

PATIENT PRESENTING CLINICAL SIGNS

Dexter Lustgarten-Perez
SPECIES
 Canine
BREED
 Chihuahua Mix
SEX
 MN
AGE
 11 years
WEIGHT
 13 #

History: Back pain.
 Physical Examination: N/A.
 Urinalysis: N/A.
 CBC: N/A.
 Serum Biochemistry: N/A.
 Radiographic Findings: Mass effect near left kidney.

ULTRASONOGRAPHIC EXAMINATION OF THE ABDOMEN

Urinary System

Full urinary bladder with a thickened and irregular apical wall. Rest of the wall has a normal thickness and appearance. Normal anechoic urine with no sediment or uroliths evident.

Normal trigone area, proximal urethra (0.4 cm), and iliac blood vessels.

Normal iliac lymph nodes (1.2 cm). Ureters not visualized.

Left kidney – enlarged, irregular, and cystic, with largest cyst measuring 4.6 x 5.5 cm.

Right kidney – normal size (3.7 cm) with increased echogenic appearance, some loss of cortico-medullary differentiation, irregular capsule, and normal pelvis and capsule. Few small (0.5 cm) cortical cysts and faint pinpoint mineralization.

Reproductive System

Small hypoechogenic prostate (0.7 cm).

Adrenal Glands

Normal shape, echogenic appearance, size, and position. Left 0.57/0.45 cm, right 0.59/0.64 cm.

Spleen

Normal size (1.2 cm) and echogenic appearance. Smooth homogenous parenchyma, smooth curvi-linear capsule, and normal vasculature. No evidence of inflammatory, neoplastic, infarction, or infiltrative changes noted

Liver

Normal size, echogenic appearance, and portal markings. No nodules or masses evident. Full gall bladder containing normal anechoic bile. Normal thickness and echogenic appearance of the gall bladder wall. Normal bile duct (0.2 cm).

INTERPRETED BY

Remo Lobetti, BVSc,
MMedVet (Med), PhD, Dipl.
ECVIM

IMAGING PERFORMED BY

Sonya Myers, DVM

HOSPITAL NAME

Oviedo Veterinary Care and
Emergency

REFERRING VET

Dr Jones

INVOICE

303053

DATE

6/23/22


PATIENT *Gastrointestinal*

Dexter Lustgarten-Perez

Normal appearance of the stomach, duodenum, small intestine, ileo-cecal junction, and colon with no loss of layering, normal wall thickness (duodenum 0.38 cm, jejunum 0.35 cm) and peristaltic activity, and no distension of the lumen.

SPECIES

Canine

Pancreas

Normal size (right 1.1 cm) and echogenic appearance. Normal echogenic appearance of the mesentery and fat surrounding the pancreas.

BREED

Chihuahua Mix

Free Abdomen
SEX

Normal mesenteric lymph nodes (3.3 cm).
No ascites.

MN
AGE

11 years

ULTRASONOGRAPHIC FINDINGS
WEIGHT

13 #

- Primary Findings:
- Cystitis
 - Cystic left kidney.
 - Age-related renal changes vs renal disease of the right kidney.

Secondary Findings:

- None.

INTERPRETED BY

Remo Lobetti, BVSc,
MMedVet (Med), PhD, Dipl.
ECVIM

INTERPRETATION OF THE FINDINGS & FURTHER RECOMMENDATIONS
IMAGING PERFORMED BY

Sonya Myers, DVM

The appearance of the urinary bladder is consistent with cystitis with emerging neoplasia a differential diagnosis.

HOSPITAL NAME

The appearance of the left kidney would be consistent with unilateral end-stage cystic disease.

Oviedo Veterinary Care and
Emergency

Although the presenting clinical signs can be ascribed to the cystic left kidney, spinal disease (IVDD, neoplasia, trauma, focal meningitis) would need to be considered.

REFERRING VET

Dr Jones

Further assessment would be urinalysis, urine culture, neurological examination, and BRAF assessment. Drainage of the renal cysts could be considered, which is usually temporary as they generally fill up again.

INVOICE

303053

Specific therapy that could be considered (if renal function is normal, there is no spinal disease, and with a response to drainage of the cysts) would be left nephrectomy

DATE

6/23/22



PATIENT

Dexter Lustgarten-Perez

SPECIES

Canine

BREED

Chihuahua Mix

SEX

MN

AGE

11 years

WEIGHT

13 #

INTERPRETED BY

Remo Lobetti, BVSc,
 MMedVet (Med), PhD, Dipl.
 ECVIM

IMAGING PERFORMED BY

Sonya Myers, DVM

HOSPITAL NAME

Oviedo Veterinary Care and
 Emergency

REFERRING VET

Dr Jones

INVOICE

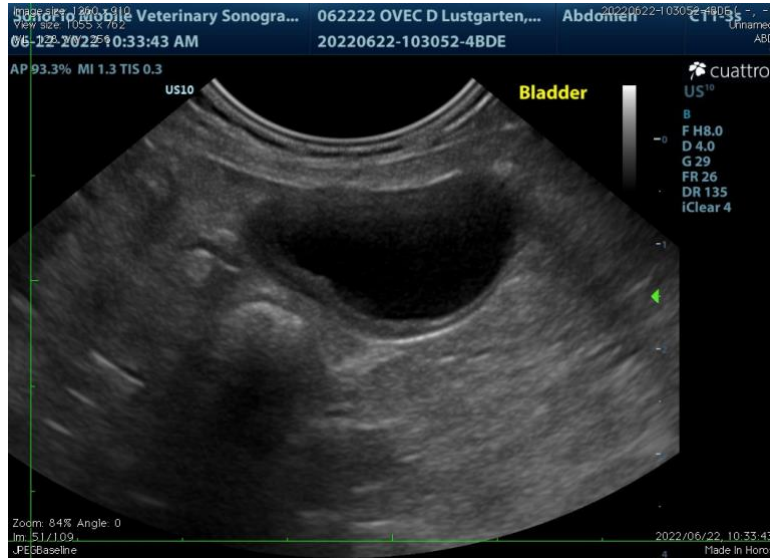303053

DATE

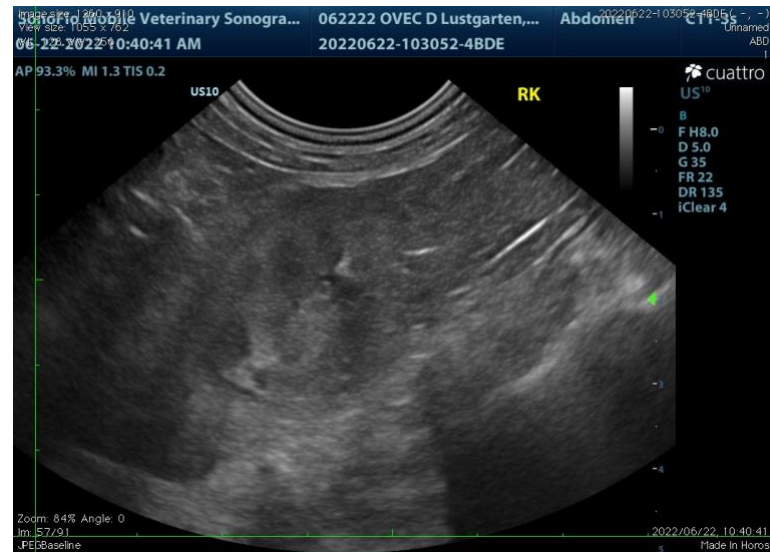6/23/22

IMAGES

Urinary bladder



Right kidney





PATIENT Left kidney

Dexter Lustgarten-Perez

SPECIES

Canine

BREED

Chihuahua Mix

SEX

MN

AGE

11 years

WEIGHT

13 #

INTERPRETED BY

Remo Lobetti, BVSc,
 MMedVet (Med), PhD, Dipl.
 ECVIM

IMAGING PERFORMED BY

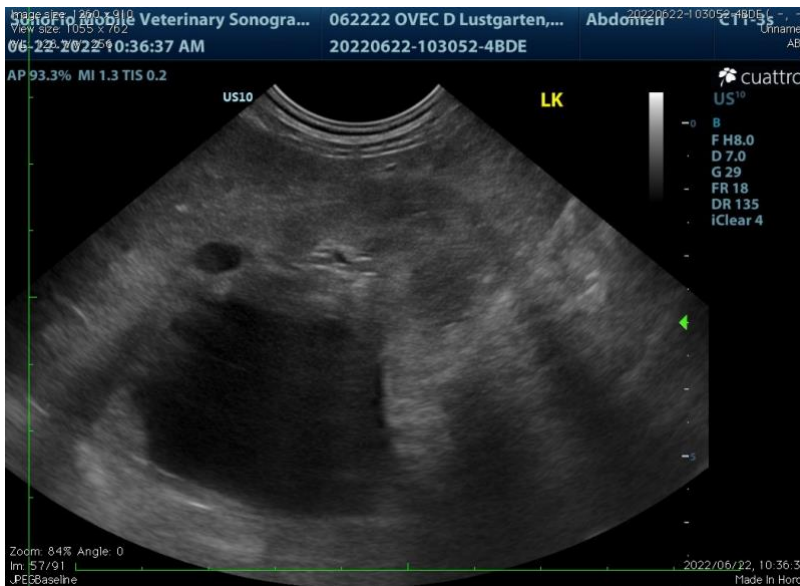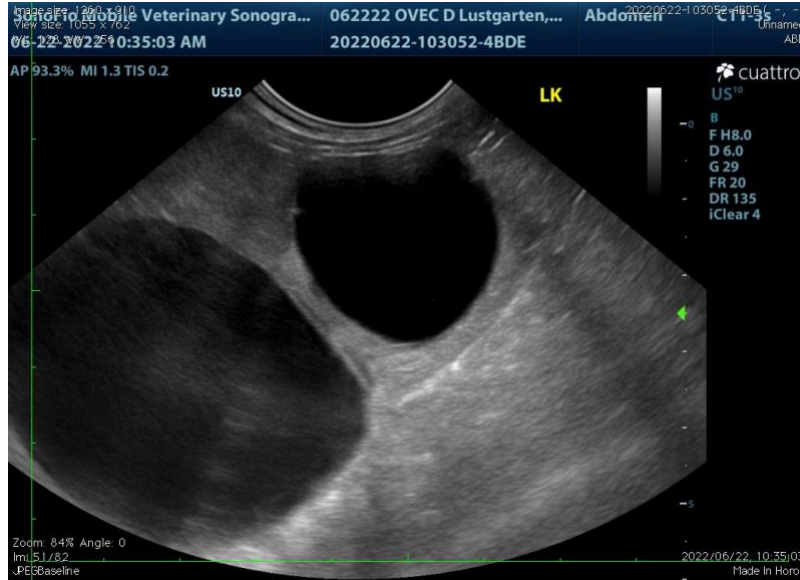
Sonya Myers, DVM

HOSPITAL NAME

Oviedo Veterinary Care and
 Emergency

REFERRING VET

Dr Jones



INVOICE

303053

DATE

6/23/22

The information and recommendations provided are based on the images presented by the referring veterinarian. No evaluation can be communicated regarding pathology that was not visible in the image/video clips provided.

Thank you for this referral. If the clinical or image interpretation does not parallel your findings or if I can be of any further assistance, please contact me.

Remo Lobetti, BVSc, MMedVet (Med), PhD, Dipl. ECVIM (Internal Medicine)
rlobetti@mweb.co.za